


Percutaneous Cement Discoplasty for the Treatment of Advanced Degenerative Disc Conditions: A Case Series Analysis

Global Spine Journal
2020, Vol. 10(6) 729-734
© The Author(s) 2019
Article reuse guidelines:
sagepub.com/journals-permissions
DOI: 10.1177/2192568219873885
journals.sagepub.com/home/gsj



Gaston Camino Willhuber, MD¹ , Gonzalo Kido, MD¹,
Matias Pereira Duarte, MD¹, Martin Estefan, MD¹,
Mariana Bendersky, PhD, MD¹, Julio Bassani, MD¹,
Matias Petracchi, MD¹, Marcelo Gruenberg, MD¹, and Carlos Sola, MD¹

Abstract

Study Design: Retrospective analysis. Level of evidence III.

Objectives: To describe the results after a minimum 1-year follow-up in patients treated with percutaneous discoplasty (PD), a minimally invasive technique to treat low back pain in elderly patients with advanced degenerative disc disease. The procedure consists in improving stability by injecting bone cement in a severely degenerated pneumodisc. There are few reports in the literature about this technique.

Methods: Fifty-four patients with advanced disc disease with/without degenerative scoliosis treated with PD with at least 1 year follow-up were studied, variables included clinical (visual analogue scale [VAS] and Oswestry Disability Index [ODI]) and radiological parameters (lumbar lordosis and Cobb angle), as well as hospital length of stay and complications.

Results: At 1-year postoperation, significant pain reduction (VAS: preoperative 7.8 ± 0.90 ; postoperative 4.4 ± 2.18) and improvement in the ODI (preoperative 62 ± 7.12 ; postoperative 36.2 ± 15.47) were observed with partial correction of radiological parameters (5° mean increase in lumbar lordosis and decrease in Cobb angle). Mean surgical time was 38 minutes, and the mean length of hospital stay was 1.2 days.

Conclusion: PD, currently not a very well-known technique, appears to be—at least in the short-term follow-up—an effective treatment option in selected cases with low back pain due to advanced degenerative disc disease.

Keywords

percutaneous discoplasty, advanced disc disease, minimally invasive surgery, cement spacer, degenerative scoliosis

Introduction

Chronic low back pain (LBP) secondary to degenerative conditions is a common complaint among elderly patients.¹ Surgical management is considered only when conservative treatment is not effective and targeting the pain source is possible. In this scenario, the standard approach usually implies performing a vertebral fusion, with or without reconstructive procedures. Along with a population that is aging but wants to stay active, surgical treatments have extended to elderly patients, but they are associated with higher morbidity in this age group,²⁻⁵ making them a challenging or even unviable option. Although minimally invasive surgery is associated with

reduced risks and hospitalization time,⁶⁻⁹ it is not exempt from complications inherent to fusion or instrumentation.^{10,11}

Among elderly patients with severe mechanical LBP a group of subjects with imaging and clinical findings

¹ Hospital Italiano de Buenos Aires, Buenos Aires, Argentina

Corresponding Author:

Gaston Camino Willhuber, MD, Orthopaedic and Traumatology Department, Institute of Orthopedics “Carlos E. Ottolenghi” Hospital Italiano de Buenos Aires, Buenos Aires, Argentina.
Email: gaston.camino@hospitalitaliano.org.ar



suggestive of mechanical instability can be identified. Those findings are: type 1 modic change, vacuum phenomenon (mandatory), variation in intervertebral disc alignment between standing and supine X-rays (accordion phenomenon), and LBP that increases with standing activity and is relieved after resting or using a spinal orthosis. Percutaneous discoplasty (PD) is a minimally invasive technique developed by Varga et al¹² as an alternative treatment to reduce pain and disability in degenerative lumbar disk pathology, and it can be considered as an option for this group of patients. The aim of this study is to present, through a case series, the postoperative results of 54 patients with advanced degenerative lumbar conditions treated only with PD. Our hypothesis is that PD can improve pain and functional outcomes with low rate of major complications.

Materials and Methods

After approval from the institutional ethic review board (protocol number IRB 0003728), a prospective case-series analysis was conducted. Between December 2015 and September 2017, 82 patients (205 levels) were treated with PD. Inclusion criteria were the following:

- Patients older than 65 years
- History of mechanical low back pain reluctant to a minimum of 6 months of conservative treatment
- Tomographic evidence of vacuum phenomenon and subchondral sclerosis at the affected level
- Variation in intervertebral disc alignment at the levels involved between standing and supine radiographs in both anteroposterior and lateral views (accordion phenomenon).

Exclusion criteria were the following:

- Patients with less than 1 year of follow-up
- Discoplasty performed simultaneously with another procedure such as arthrodesis or decompression
- Patient with previous surgery at the same anatomical region

LBP was evaluated with the visual analogue scale (VAS) of pain preoperatively, at 1 week postoperatively, and at the last clinical visit with a minimum of 1 year. Functional results were measured with the Oswestry Disability Index (ODI) score preoperatively and after at least 1 year (Figures 1 and 2).¹³

Radiographic measurements in pre- and postoperative standing whole body X-rays included the following parameters: C7 plumb line and sagittal vertical axis to assess sagittal and coronal balance, lumbar lordosis, lumbar/thoracolumbar scoliosis, segmental scoliotic Cobb angle, and segmental lordosis (Figure 3) and pelvic parameters (sacral slope, pelvic incidence, pelvic tilt) (Figure 4). Based on the diagnosis, 2 groups were created: the scoliotic group with 37 cases of degenerative scoliosis, and a nonscoliotic group with 15 cases of advanced degenerative disc

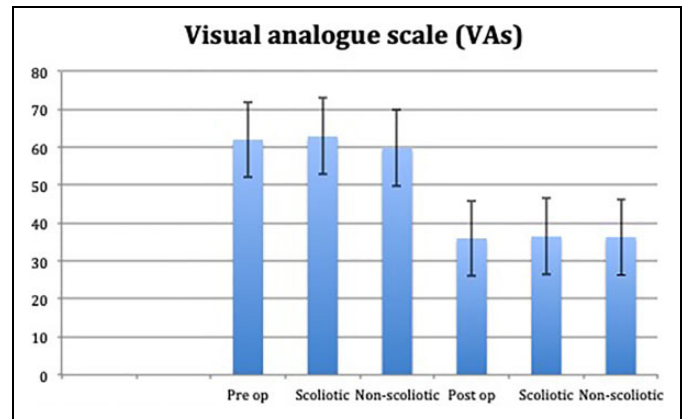


Figure 1. Visual analogue scale (VAS) score, the mean \pm SD preoperative value (7.8 ± 0.90), immediate and 1-year postoperative values of 3.8 ± 2.38 and 4.4 ± 2.18 , respectively ($P < .0001$). No differences were observed in the scoliotic and nonscoliotic groups.

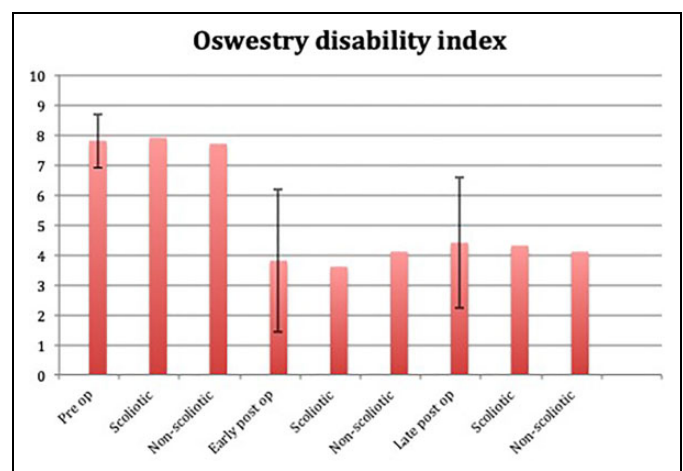


Figure 2. Preoperative (62 ± 7.12) and 1-year postoperative (36.2 ± 15.47) Oswestry Disability Index scores with a mean improvement of 42% ($P < .0001$). No differences were observed in the scoliotic and nonscoliotic groups.

disease without scoliosis plus 2 cases of degenerative spondylolisthesis. Radiological and clinical parameters were reevaluated at 1-year postoperatively.

In addition, we evaluated the operating room time for the procedure, hospital length of stay, and postoperative complications.

Operative Procedure

For a detailed description of the procedure see the technical note previously described by the authors.¹⁴

Discoplasties were performed under general intravenous anesthesia, with patients positioned in a frame with 2 rolls plus an inflatable roll under the thigh region, this roll was inflated or deflated in order to increase or decrease lumbar lordosis and disc space height. Under fluoroscopic vision and neurophysiological monitoring, according to the technique previously described by Varga et al¹² with modifications by the

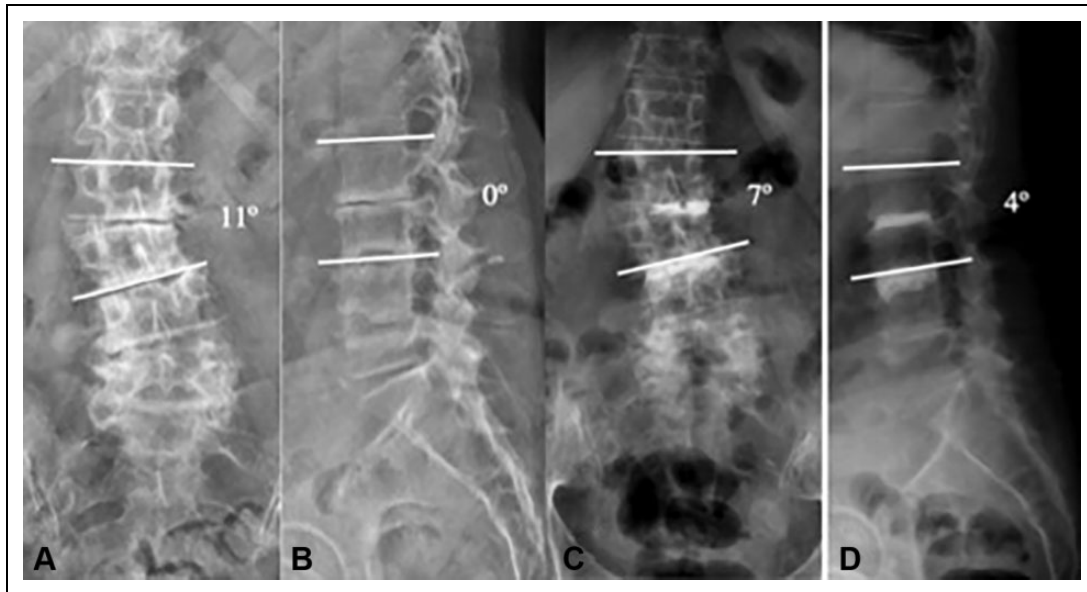


Figure 3. (A-D) Anteroposterior and lateral standing lumbar X-rays showing segmental changes in alignment at the L2-L3 affected level before and after percutaneous discoplasty.

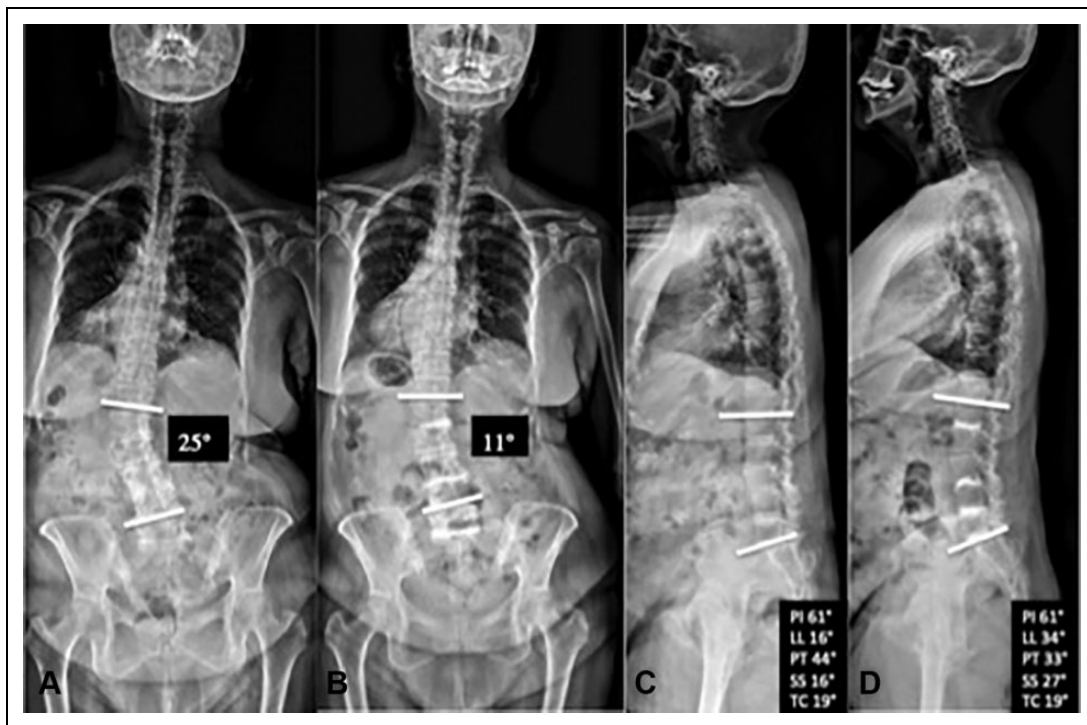


Figure 4. Preoperative and postoperative X-rays of a 78-year-old woman with degenerative scoliosis on whom L1-L2 and L3-S1 discoplasties were performed. Improvement in lumbar lordosis and scoliosis curve is observed.

authors,¹⁴ a Jamshidi cannulated needle was placed at each compromised intervertebral disc. Polymethylmethacrylate (PMMA) (Kyphon HV-R Bone Cement) was slowly injected through the cannula with special attention to detect any sign of cement leakage into the canal or the foraminal space. After the procedure patients were encouraged to stand and walk as soon as possible.

Statistical Analysis

A 2-tailed *t* test for paired samples with a confidence interval of 95% was employed to compare pre- and postoperative results in the VAS scale and ODI, and for the analysis of the pre and postoperative scoliotic Cobb angle and lumbar lordosis in scoliotic and nonscoliotic groups.

Table 1. Preoperative and Postoperative Radiological Parameters.

Parameters	Overall		Scoliotic Group		Nonscoliotic Group	
	Preoperative	Postoperative	Preoperative	Postoperative	Preoperative	Postoperative
Lumbar lordosis, deg	39.09 (3-83)	44.2 (19-77)	34.8 (3-71)	41.2 (19-70)	48.2 (21-83)	50.8 (27-77)
Cobb angle, deg	24.1 (0-92)	19.5 (0-102)	29.7 (0-92)	24 (0-102)	12 (0-44)	9.7 (0-52)
Pelvic incidence, deg	54.2 (26-89)	—	53.8 (26-89)	—	55.6 (44-79)	—
Sacral slope, deg	28.3 (6-52)	29.3 (9-49)	27 (10-52)	28.3 (9-49)	31.1 (6-46)	31.4 (10-43)
C7 plumb line (mean sagittal balance), mm	53	43	62.1	50.3	37.7	29.5
Sagittal vertical axis (mean coronal balance), mm	18.2	16.4	21	19	10.8	10.5

Table 2. Segmental Preoperative and Postoperative Anteroposterior and Sagittal Angulation According to Level of Discoplasty.

Level	Number	Mean Preoperative Cobb Angle	Mean Postoperative Cobb Angle	P	Mean Preoperative Lordosis	Mean Postoperative Lordosis	P
T12-L1	5	2.2 (0-5)	0.9 (0-3)	.6	0.3 (0-3)	1.1 (0-2)	.30
L1-L2	16	2.1 (0-5)	2.1 (0-3)	.82	2.7 (0-4)	2.8 (1-4)	.13
L2-L3	29	9.2 (0-12)	7.1 (0-11)	.52	4.1 (1-6)	4.3 (2-6)	.26
L3-L4	26	8.2 (1-17)	6.3 (1-8)	.30	7.2 (1-10)	7.9 (3-15)	.20
L4-L5	32	3.3 (0-6)	2.5 (0-6)	.26	10.3 (5-19)	12.3 (6-19)	.1
L5-S1	23	0.5 (0-2)	0.4 (0-2)	.90	15.2 (5-23)	17.8 (11-25)	.09

P values $\leq .05$ were considered as statistically significant. All statistical analysis was performed using IBM SPSS Statistics software (v.22, IBM, Armonk, NY, USA).

Results

Out of the 82 patients treated, 15 had previous arthrodesis in the same anatomical area, 6 cases had nonunion, 5 cases had less than 1 year of follow-up, and 2 patients were lost during follow-up. Fifty-four patients fulfilled the inclusion criteria: 11 males and 43 females with a mean age of 76 years (range 69-87 years). A total of 131 levels were treated, with an average of 2.5 levels per patient (range of 1-5 levels). PD was performed in 5 patients at the T12-L1 level; 16 patients at L1-L2; 29 patients at L2-L3; 26 patients at L3-L4; 32 patients at L4-L5, and 23 patients at L5-S1.

The average operating room time was 38 minutes (range 18-52 minutes). The mean follow-up was 16.8 months \pm 3.3 (range 12-21 months).

Visual Analogue Scale and Oswestry Scores

Average preoperative LBP, VAS score was 7.8 ± 0.90 , immediately and 1-year postoperation values were 3.8 ± 2.38 and 4.4 ± 2.18 , respectively, with a final mean improvement of 3.4 points ($P < .0001$, 95% CI, 2.87-4.06) (Figure 1).

ODI score improved significantly from 62 ± 7.12 preoperative to 36.2 ± 15.47 at 1-year postoperation ($P < .0001$, 95% CI, 21.32-29.71) (Figure 2). No significant differences were found between the scoliotic and nonscoliotic groups when comparing VAS or ODI ($P > .05$).

Radiological Parameters

Table 1 shows the average pre- and postoperative radiological parameters. An increase in lumbar lordosis of 5.1° was observed and a 5° improvement of the scoliosis at 1 year follow-up was observed. In the scoliotic group, significant differences were observed in the preoperative and postoperative scoliotic Cobb angle ($P = .0006$; 95% CI, 2.65-8.86). Lumbar lordosis improvement was also significant ($P = .0001$). On the other hand, the nonscoliotic group showed no significant differences in terms of preoperative and 1 year postoperative Cobb angle ($P = .1006$) and lumbar lordosis ($P = .0854$). Table 2 shows segmental angulation in anteroposterior and lateral X-rays in all treated levels. Segmental angulation analyzed per level showed no significant differences between preoperative and 1-year postoperative ($P > .05$).

Hospital Length of Stay and Complication Rate

Most patients (81%) were discharged during the first 24 hours, 8 patients (15%) were discharged at the second day, and 2 patients (4%) at the third day.

Four cases required foraminal decompression due to radicular symptoms within 90 days (7.4%), within these cases; 2 had cement leakage to the foramen, 1 case experienced a disc extrusion, and 1 case had LBP relief but persistent sciatic pain that required foraminal decompression.

One patient presented a deep infection and 1 patient presented a vertebral fracture adjacent to the discoplasty that required a vertebroplasty. There were no cases of clinical complications such as pneumonia, urinary infection, venous thrombosis, and so on.

Case Presentation

A 78-year-old woman with a history of chronic LBP, unresponsive to conservative treatment was referred to our outpatient clinic. Pain was rated 7/10 in standing position and improved to 3/10 with resting in horizontal position.

A 25° lumbar degenerative scoliosis was observed in plain radiography. A computed tomography scan showed multiple level degeneration with vacuum phenomenon and subchondral sclerosis. Scoliosis curve variation between standing X-ray (25°) and horizontal computed tomography scan (11°), defined as accordion phenomenon, was identified.

PD was performed at L1-L2, L3-L4, L4-L5, and L5-S1 levels. Postoperative X-ray showed partial improvement of LL and scoliosis curve (Figure 4). The patient was discharged at 24 hours postop with significant pain relief (VAS score: 2/10 in standing position).

Discussion

The higher prevalence of patients with degenerative spinal conditions who wish to maintain their functional status has led surgeons to look for strategies to improve the quality of life in this population.¹⁵

LBP as a result of advanced degenerative changes in the intervertebral disc and/or facet joint is a common complaint among elderly patients. In this scenario, one of the most difficult challenges is to identify the pain source, particularly when multiple levels are involved.

The option of a selective fusion to treat the most compromised levels is a well-established alternative even when a deformity is present. These procedures can sometimes be performed through minimally invasive techniques; however, they still deal with complications related to fusion and instrumentation.^{10,11}

When a limited procedure is the defined strategy and we find axial instability due to severe degenerative disk disease with vacuum phenomenon and subchondral sclerosis, we consider PD as an option, especially in elderly patients in whom surgical risk is high.

Varga et al¹² first described this procedure in 2014 for the treatment of degenerative disc disease. In their series, 47 consecutive patients with back and/or leg pain due to vertical instability (vacuum phenomenon and dynamic stenosis) showed significant pain reduction after a minimum 6-month follow-up.¹² In our series, we found similar results with significant improvement in low back pain and ODI scores.

This procedure is based on the concept of disc space stabilization and partially disc height restoration by injecting the necessary amount of cement to fill the empty disc when the patient is in a lordotic prone position.

Similar to what Varga et al¹² described, a minimal correction in the scoliotic curve or lordosis improvement has been observed in our study; however, the main goal of this procedure is to decrease pain by stabilizing the treated levels, being those small radiological corrections a secondary outcome. In our study, we observed a mean of 5° of lumbar lordosis

improvement and 5° of scoliotic curve reduction. Recently, Kiss et al¹⁶ reported improvement in lumbar alignment and foraminal decompression in 28 cases treated with PD after 6-month follow-up, similar results were found in our study, especially in the scoliotic group. However, the long-term effect of discoplasty in spinopelvic balance is not well established and is beyond the objective of our study.

Unlike the study by Varga et al,¹² leg pain was not considered as a primary outcome in the present study, mainly because patients with leg pain as predominant symptom were treated with decompression associated with another procedure such as arthrodesis or even discoplasty, and hence were excluded from this study.

This technique is also presented as an alternative option in patients in whom open surgical procedures are associated with a higher complication rate or even contraindicated due to increased morbidity. Surgical treatment in elderly patients with spinal deformity has been associated with a higher rate of complications, such as postoperative infection, non-union, pneumonia, thrombosis or urinary tract infection.^{15,17} Soroceanu et al,¹⁸ in 448 patients with adult spinal deformity, observed a complication rate of 26%. Glassman et al¹⁹ reported a rate of 24.9% of both medical and surgical complications in patients with adult scoliosis (108 of 434 patients). Carreon et al²⁰ found a complication rate of 79.6% in patients older than 65 years who underwent posterior decompression and fusion, 21.4% had major complications and 50% had 2 or more complications, which were related to advanced age, blood loss, operative time, and the number of levels fused.³ Minimally invasive surgery has been developed to reduce blood loss, operative time, and complications, but is usually associated to a higher cost and is not free from complications.²¹

In our series, we had no cases of clinical complications such as pneumonia, urinary infection, or deep vein thrombosis. This could be related to the short surgical time and hospital stay; however, 4 cases required decompression surgery within 90 days due to persistence of the symptoms or, less frequently, new radicular symptoms (7.4%). Two of these 4 cases required decompression due to the presence of cement leakage, regarding this complication, we have found increased rate of cement leakage in cases with previous annulus rupture or defect secondary to an extrusion or disc surgery. Despite the fact that we did not include cases with previous surgery in the same anatomical region in this study, annulus rupture should be always considered because it could increase the risk of cement leakage.

This study has some limitations. First, the relatively short follow-up with a minimum of 1 year and an average of 16.8 months; in addition, the study population included 2 main different scenarios: degenerative scoliosis and degenerative disc disease without scoliosis, probably spinal balance plays a role in postoperative results. However, to our knowledge, few reports have been published regarding this technique, indications, and outcomes. Long-term studies are required to establish the true benefits and limitations of this procedure.

Conclusion

Percutaneous discoplasty resulted in a significant pain reduction at 1-year follow-up, with slight improvement of radiological parameters. This procedure could be an alternative option for the treatment of chronic LBP in elderly patients with advanced degenerative disc disease in whom conventional surgical treatments are associated with higher complication rates and surgical risks. Long-term follow-up studies are required to establish the real benefit of this procedure in terms of clinical improvement and radiological parameters.


Declaration of Conflicting Interests

The author(s) declared no potential conflicts of interest with respect to the research, authorship, and/or publication of this article.

Funding

The author(s) received no financial support for the research, authorship, and/or publication of this article.

ORCID iD

Gaston Camino Willhuber  <https://orcid.org/0000-0002-5684-7679>

References

- Hoy D, Bain C, Williams G, et al. A systematic review of the global prevalence of low back pain. *Arthritis Rheum.* 2012;64:2028-2037.
- Puvanesarajah V, Nourbakhsh A, Hassanzadeh H, Shimer AL, Shen FH, Singla A. Readmission rates, reasons, and risk factors in elderly patients treated with lumbar fusion for degenerative pathology. *Spine (Phila Pa 1976).* 2016;41:1933-1938.
- Puvanesarajah V, Cancienne JM, Werner BC, et al. Perioperative complications associated with posterolateral spine fusions: a study of elderly Medicare beneficiaries. *Spine (Phila Pa 1976).* 2018;43:16-21.
- Mihailidis HG, Manners S, Churilov L, Quan GMY. Is spinal surgery safe in octogenarians? *ANZ J Surg.* 2017;87:600-604.
- Passias PG, Klineberg EO, Jalai CM, et al. International Spine Study Group. Hospital readmission within 2 years following adult thoracolumbar spinal deformity surgery: prevalence, predictors, and effect on patient-derived outcome measures. *Spine (Phila Pa 1976).* 2016;41:1355-1364.
- Rodgers WB, Gerber EJ, Rodgers JA. Lumbar fusion in octogenarians. *Spine (Phila Pa 1976).* 2010;35(26 suppl):S355-S360.
- Isaacs RE, Hyde J, Goodrich JA, Rodgers WB, Phillips FM. A prospective, nonrandomized, multicenter evaluation of extreme lateral interbody fusion for the treatment of adult degenerative scoliosis: perioperative outcomes and complications. *Spine (Phila Pa 1976).* 2010;35(26 suppl):S322-S330.
- Uddin OM, Haque R, Sugrue PA, et al. Cost minimization in treatment of adult degenerative scoliosis. *J Neurosurg Spine.* 2015;23:798-806.
- Phillips FM, Isaacs RE, Rodgers WB, et al. Adult degenerative scoliosis treated with XLIF: clinical and radiographical results of a prospective multicenter study with 24-month followup. *Spine (Phila Pa 1976).* 2013;38:1853-1861.
- Knight RQ, Schwaegler P, Hanscom D, Roh J. Direct lateral lumbar interbody fusion for degenerative conditions: early complication profile. *J Spinal Disord Tech.* 2009;22:34-37.
- Cummock MD, Vanni S, Levi AD, Yu Y, Wang MY. An analysis of postoperative thigh symptoms after minimally invasive transposas lumbar interbody fusion. *J Neurosurg Spine.* 2001;15:11-18.
- Varga PP, Jakab G, Bors IB, Lazary A, Szövérfi Z. Experiences with PMMA cement as a stand-alone intervertebral spacer: percutaneous cement discoplasty in the case of vacuum phenomenon within lumbar intervertebral discs. *Orthopade.* 2015;44(suppl 1):S1-S7.
- Fairbank JC, Pynsent PB. The Oswestry Disability Index. *Spine (Phila Pa 1976).* 2000;25:2940-2952.
- Sola C, Camino Willhuber G, Kido G, et al. Percutaneous cement discoplasty for the treatment of advanced degenerative disk disease in elderly patients [published online March 23, 2018]. *Eur Spine J.* doi:10.1007/s00586-018-5547-7
- Daubs MD, Lenke LG, Cheh G, Stobbs G, Bridwell KH. Adult spinal deformity surgery: complications and outcomes in patients over age 60. *Spine (Phila Pa 1976).* 2007;32:2238-2244.
- Kiss L, Varga PP, Szoverfi Z, Jakab G, Eltes PE, Lazary A. Indirect foraminal decompression and improvement in the lumbar alignment after percutaneous cement discoplasty. *Eur Spine J.* 2019;28:1441-1447.
- Pateder DB, Gonzales RA, Kebaish KM, et al. Pulmonary embolism after adult spinal deformity surgery. *Spine (Phila Pa 1976).* 2008;33:301-305.
- Soroceanu A, Burton DC, Oren JH, et al; International Spine Study Group. International Spine Study Group. Medical complications after adult spinal deformity surgery: incidence, risk factors, and clinical impact. *Spine (Phila Pa 1976).* 2016;41:1718-1723.
- Glassman SD, Hamill CL, Bridwell KH, Schwab FJ, Dimar JR, Lowe TG. The impact of perioperative complications on clinical outcome in adult deformity surgery. *Spine (Phila Pa 1976).* 2007;32:2764-2770.
- Carreon LY, Puno RM, Dimar JR 2nd, Glassman SD, Johnson JR. Perioperative complications of posterior lumbar decompression and arthrodesis in older adults. *J Bone Joint Surg Am.* 2003;85:2089-2092.
- Rosen DS, O'Toole JE, Eichholz KM, et al. Minimally invasive lumbar spinal decompression in the elderly: outcomes of 50 patients aged 75 years and older. *Neurosurgery.* 2007;60:503-510.